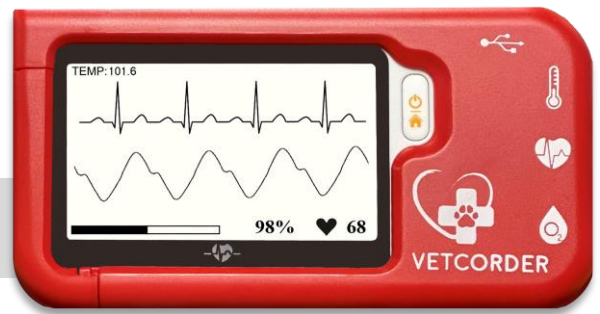


Use cases from the clinic and field



Remote monitoring of a patient in isolation

Background

Nicole Schneider is a Certified Veterinary Technician (CVT) at the Kuenzi Family Pet Hospital. Like most CVTs, her responsibilities are many and varied. A typical day will find her performing laboratory diagnostics, assisting in surgery, providing anesthetic monitoring, and caring for hospitalized patients.

Clinical Story

On a completely scheduled outpatient day, Nicole was tasked to triage a four-year-old, male, neutered English Springer Spaniel, named Augie. He presented with vomiting and diarrhea. In the exam room the dog was trembling and weak, with a greater than 4 second skin tent and tacky pale mucous membranes. His rectal temperature was just 95° F, and a reliable reading of blood pressure was not able to be ascertained after several attempts. The dog passed a small amount of bloody diarrhea in the exam room. Upon consulting with the admitting Veterinarian, Augie was hospitalized. Blood and stool were submitted to the lab, abdominal radiographs were taken, IV fluids were started, and a Vetcorder was placed on Augie. It was immediately noted that he was having intermittent VPCs; approximately 5-7 per minute. A few minutes later, lab results found both Giardia Trophozoites, and Clostridium. Clinically, it was presumed that the arrhythmia was due to dehydration and abdominal pain. The patient was moved to isolation on IV fluids, IV Metronidazole, and SQ Torbugesic. The Vetcorder remained on the patient and Nicole continued to monitor his vitals via Bluetooth connection to the clinic portable tablet, while she went about her other duties at the hospital.

During the course of the afternoon, the frequency of the arrhythmias decreased, and Augie's strength and attitude improved. After 24 hours in the Isolation Ward, he had no more arrhythmias and began to eat. He was discharged from the hospital on oral medication and home care.

Results

The patient has made a full recovery. Augie is now Giardia free, eating well, active and with normal cardiac rates and rhythms. The Vetcorder improved patient care by quickly identifying abnormal vital signs and allowing constant patient monitoring without having to stay in or frequently re-enter the isolation ward.



“My Vetcorder is always with me. We continually find new ways to use them to provide better patient care and improve our efficiency.”

*Nicole Schneider, CVT
Kuenzi Family Pet Hospital*

